

Predictive Value of Recurrent Acute Cerebral Hemorrhage: A Study Based on Electrocardiogram

Lu Ganggui^{1,a}, Song Zhao^{1,b}, Zhang Yuelin^{1,c,*}

¹Department of Neurosurgery, Xi'an Medical University, Xi'an, Shaanxi, 710021, China
^a2099819214@qq.com, ^b1033308149@qq.com, ^czhangyuelin68@163.com

*Corresponding author

Keywords: Acute cerebral hemorrhage; Rebleeding; Electrocardiogram; Predictive value; Nervous system diseases

Abstract: Acute cerebral hemorrhage is a serious neurological disease with a high risk of recurrent bleeding. As a common clinical test, the importance of electrocardiogram in predicting recurrent bleeding in acute cerebral hemorrhage has gradually come to the fore. This paper provides a comprehensive review of the recent research progress in predicting recurrent bleeding in acute cerebral hemorrhage, emphasizing the application of electrocardiogram in this prediction and its clinical value.

1. Introduction

Acute cerebral hemorrhage (ACH) is a serious neurological condition, imposing a significant burden on patients and their families due to its high rates of disability and mortality [1,2], as shown in Figure 1. Rebleeding is a common issue encountered during the treatment of acute cerebral hemorrhage patients, and it is also an important factor that affects the prognosis of these patients [3,4]. It is therefore crucial to predict the risk of rebleeding in acute cerebral hemorrhage patients. Currently, methods for predicting rebleeding are primarily based on imaging and blood biochemical indices, among others [5,6]. Nevertheless, these methods possess certain limitations and are unable to accurately predict the risk of rebleeding in patients. In recent years, electrocardiography, being a noninvasive, simple, and easily reproducible examination method, has gained increasing attention in predicting acute cerebral hemorrhage rebleeding [7,8]. The objective of this study is to examine the value of electrocardiography in predicting acute cerebral hemorrhage rebleeding and to explore the independent predictive value of electrocardiography in this context. Through this study, we aim to gain a deeper understanding of the electrocardiographic characteristics of acute cerebral hemorrhage patients and provide clinicians with a more accurate and reliable method for predicting acute cerebral hemorrhage rebleeding. The goal is to formulate a more rational treatment plan for patients, reduce the risk of rebleeding, and enhance the quality of life of these patients.

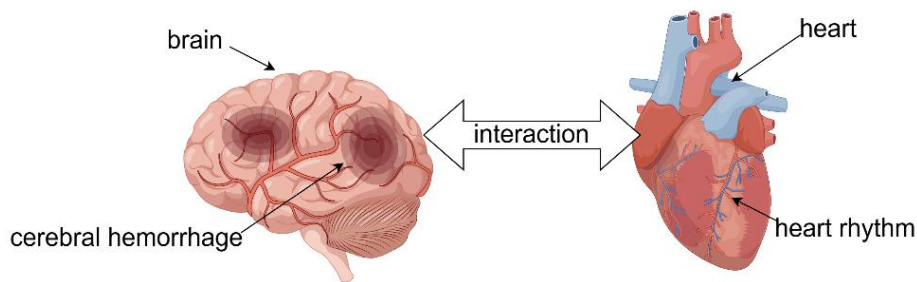


Figure 1: Acute cerebral hemorrhage (ACH)

2. Cerebral hemorrhage rebleeding in relation to the electrocardiogram.

Cerebral hemorrhage refers to bleeding resulting from the rupture of a blood vessel within the skull, often resulting in severe neurological damage [9]. Rebleeding, conversely, refers to the recurrence of a brain hemorrhage following a cerebral hemorrhage. This condition is typically caused by either the re-rupture of a blood vessel at the original site or the rupture of a new blood vessel [10]. The recurrence of a brain hemorrhage, known as rebleeding, poses a severe risk due to its potential to cause even more severe neurological damage and higher mortality rates [11].

Rebleeding from a brain hemorrhage can result from a range of causes, with the most prevalent being high blood pressure and the hardening of arteries. High blood pressure can lead to the walls of blood vessels becoming thinner and harder, thereby elevating the risk of rupture. Conversely, atherosclerosis can result in the walls of blood vessels becoming weaker and thus more susceptible to rupture. Furthermore, other causes encompass cerebrovascular malformations, rare disorders like smokers' disease, and the inappropriate use of anticoagulant medications.

In the management of cerebral hemorrhage with risk of rebleeding, emergency surgical intervention is essential to eliminate the hematoma and control intraoperative bleeding. Prior to surgery, the surgeon carefully assesses the patient's condition and devises an individualized treatment plan customized according to the patient's unique clinical situation [12,13]. Following surgery, patients typically require prolonged rehabilitation and care in order to optimize neurological recovery and enhance quality of life.

In summary, recurrent bleeding from cerebral hemorrhage is a life-threatening condition that warrants prompt treatment. For individuals with hypertension and atherosclerosis, proactive management of blood pressure and treatment of atherosclerosis are imperative to mitigate the risk of recurrent brain hemorrhage. Additionally, individuals who have experienced a cerebral hemorrhage should undergo regular check-ups and follow-up assessments to facilitate the timely detection and treatment of recurrent brain hemorrhages.

Electrocardiography (ECG) is a non-invasive medical test employed to evaluate the electrical activity of the heart [14]. It is a widely used diagnostic tool that holds significant importance in the evaluation of cardiac diseases, arrhythmias, myocardial infarction, and other disorders. By recording the electrical activity of the heart, ECG can detect abnormal heart rhythms, conduction blocks, and so forth [15,16]. In clinical practice, electrocardiography is frequently employed as a preferred method for assessing cardiovascular diseases.

Electrocardiography (ECG) has a wide range of applications, not only for the evaluation of patients with cardiovascular disease, but also for the supplementary diagnosis of other disorders. For instance, in neurological disorders, ECG testing can be used to assess conditions like insufficient cerebral blood supply and epilepsy [17,18]. Additionally, ECG examination can assist in assessing cardiovascular

diseases during pregnancy in expectant mothers [19,20]. In summary, ECG examination is a non-invasive, safe, dependable, and expeditious medical diagnostic method, which holds great significance for the evaluation of cardiovascular and cerebrovascular diseases as well as other disorders.

Electrocardiograms are used to obtain information about heart function and rhythm, enabling doctors to better diagnose and treat cerebral hemorrhage rebleeding. Cerebral hemorrhage rebleeding is a serious condition that is closely linked to abnormalities in heart function and rhythm. During cerebral hemorrhage rebleeding, cardiac dysfunction and arrhythmia frequently endanger the patient's life. Hence, electrocardiograms are crucial for the diagnosis and treatment of cerebral hemorrhage rebleeding. The identification and management of these disorders are imperative to avert cerebral hemorrhage rebleeding.

Additionally, an electrocardiogram (EKG) test can assist doctors in assessing the severity of recurrent brain hemorrhage. In cases where recurrent brain hemorrhage is severe, the patient's cardiac function and heart rhythm may become abnormal, which can be detected through ECG. Physicians can formulate a more precise treatment plan using the results of the ECG. In patients with acute cerebral hemorrhage, alterations in the ECG can indicate both the patient's current condition and prognosis.

3. Electrocardiography in the prediction of rebleeding in acute cerebral hemorrhage

Currently, studies on the application of ECG to predicting rebleeding in acute cerebral hemorrhage fall into two main categories: those utilizing traditional ECG parameters, such as heart rate, rhythm, QT interval and those employing novel ECG indices [21,22], including cardiac autonomic tone and electrocardiographic information entropy [23,24].

3.1. Predictive value of traditional electrocardiographic indices in cerebral hemorrhage rebleeding

3.1.1. Heart rate and cerebral hemorrhage rebleeding

Heart rate refers to the number of times the heart beats per minute, which is one of the most crucial and elementary metrics in electrocardiography. Multiple studies have demonstrated a robust correlation between a rapid heart rate and the risk of recurrent bleeding in patients with cerebral hemorrhage. For instance, a substantial cohort study on patients with cerebral hemorrhage revealed that the risk of recurrent bleeding was significantly higher in individuals with higher heart rates compared to those with lower heart rates [25]. Furthermore, another study has demonstrated a direct correlation between a faster heart rate and the risk of recurrent bleeding [26]. The risk of recurrent bleeding has been found to be significantly higher in patients with higher heart rates compared to those with lower heart rates. cerebral hemorrhage, existing literature indicates that an elevated heart rate exerts pressure on cerebral blood vessels, thereby augmenting the likelihood of recurrent hemorrhage. Nevertheless, the precise underlying mechanism necessitates additional investigation. Regarding the association between heart rate and the occurrence of recurrent cerebral hemorrhage, empirical studies have demonstrated that an elevation in heart rate is positively correlated with an increased incidence of recurrent cerebral hemorrhage. Concerning the connection between heart rate variability and recurrent cerebral hemorrhage, further research is warranted. Regarding the correlation between heart rate variability and recurrent cerebral hemorrhage, a decrease in heart rate variability has been found to elevate the likelihood of recurrent cerebral hemorrhage. Nevertheless, the precise mechanism underlying this phenomenon necessitates additional investigation. Concerning the association between heart rate and the prognosis of individuals afflicted with recurrent cerebral

hemorrhage, the majority of studies have indicated that an elevation in heart rate can influence the prognosis of such patients. However, the precise manner and extent of this influence warrant further exploration. In conclusion, the intricate association between heart rate and recurrent cerebral hemorrhage necessitates additional comprehensive investigation. Thoroughly examining the underlying mechanism through which heart rate impacts the occurrence of recurrent cerebral hemorrhage may yield novel insights and approaches for the prevention and treatment of this condition.

3.1.2. Heart Rhythm and Cerebral Hemorrhage Rebleeding

Cardiac rhythm refers to the pattern of heartbeats, which encompasses sinus rhythm, atrial fibrillation, and ventricular fibrillation. Patients with cerebral hemorrhage and concurrent arrhythmia are faced with a larger risk of subsequent bleeding episodes. The elevated risk could be attributed to fluctuating blood pressure and altered hemodynamics induced by arrhythmia, thereby escalating the likelihood of recurrent intracranial vessel rupture. Arrhythmia could additionally influence treatment strategies and prognosis for these patients; for instance, anticoagulant usage can potentially amplify the re-bleeding risk. Foreseeing the re-bleeding risk is vital for cerebral hemorrhage patients, wherein arrhythmia could prove to be an insightful predictive marker. Findings exhibit an elevated re-bleeding risk among arrhythmic patients, potentially correlating with elements like blood pressure instability and arrhythmia-induced hemodynamic alterations. Furthermore, arrhythmia can impact treatment modalities and patient prognosis; for instance, anticoagulant use might exacerbate the risk of re-bleeding. Hence, vigilant arrhythmia surveillance in cerebral hemorrhage patients coupled with appropriate therapeutic interventions could aid in mitigating the re-bleeding risk. In conclusion, the prognostic value of arrhythmia in predicting cerebral hemorrhage re-bleeds warrants consideration. Continuous monitoring of arrhythmia and application of intervention strategies tailored to the patient's condition may serve to decrease the likelihood of re-bleeding. Multiple studies have demonstrated a correlation between cardiac arrhythmias and the risk of rebleeding in patients with cerebral hemorrhage. A clinical study of patients with cerebral hemorrhage, for instance, revealed a correlation between the presence of arrhythmias and the risk of mortality due to rebleeding [27,28]. Furthermore, another study involving patients with cerebral hemorrhage demonstrated a strong association between arrhythmias like atrial fibrillation and ventricular fibrillation with the risk of rebleeding [29,30].

3.1.3. QT interval and cerebral hemorrhage rebleeding

The QT interval, measured from the beginning of the Q wave to the end of the T wave in an electrocardiogram (ECG), is a crucial indicator of the heart's electrophysiological activity. Various factors can influence the changes in the QT interval during cerebral hemorrhage. Increased intracranial pressure can affect cardiac function and modify the QT interval. Autonomic dysfunction, resulting from cerebral hemorrhage, can impact cardiac electrophysiological characteristics. Therefore, changes in the QT interval can serve as an indicator of the severity of cerebral hemorrhage. Regular electrocardiography monitoring for patients with cerebral hemorrhage can promptly detect changes in the QT interval and predict the risk of rebleeding. Timely measures, such as reducing intracranial pressure and improving cerebral perfusion, can lower the risk of rebleeding. In summary, the prediction of rebleeding in cerebral hemorrhage holds certain value in relation to the QT interval. Monitoring electrocardiography enables prompt detection of changes in the QT interval, leading to the implementation of appropriate treatment measures and a reduced risk of rebleeding. Multiple studies have demonstrated a link between prolonged QT intervals and an increased risk of rebleeding in patients with cerebral hemorrhage. A longitudinal study revealed that a prolonged QT interval

elevates the risk of adverse outcomes associated with rebleeding. Similarly, another investigation further reinforced this correlation.

The current literature on the correlation between ECG indices and recurrent bleeding in cerebral hemorrhage is mixed and inconclusive. One argument is that ECG indices can offer valuable insights into the condition and prognosis of patients with cerebral hemorrhage, potentially serving as a predictor of recurrent bleeding. For instance, one study reported that individuals with abnormal ECGs exhibited a significantly increased risk of adverse outcomes resulting from recurrent bleeding compared to those with normal ECGs [31]. Conversely, several investigations have found no significant correlation between ECG indices and recurrent bleeding in cerebral hemorrhage, suggesting they cannot serve as reliable predictors. For instance, a recent clinical study of patients with cerebral hemorrhage revealed that ECG indices were not effective in anticipating the occurrence of bleeding [32].

3.2. New electrocardiographic indices for the relationship between cerebral hemorrhage rebleeding

In recent years, ECG-based indicators of cardiac autonomic tone have been shown to be effective in predicting and preventing cerebral hemorrhage rebleeding. ECG is a non-invasive method that allows for real-time monitoring of changes in cardiac autonomic tone. The cardiac autonomic tone index can reflect the activity of sympathetic and parasympathetic nerves, enabling the evaluation of patients' autonomic function status.

Multiple studies have demonstrated that patients with cerebral hemorrhage often experience a severe impact on their autonomic function state, particularly an increase in sympathetic nerve activity. The occurrence of rebleeding is closely associated with the autonomic function status of patients. As such, the ECG-based cardiac autonomic tone index can be employed to monitor the autonomic function status of patients with cerebral hemorrhage, enabling the prediction of risk for rebleeding and subsequent implementation of appropriate preventive measures.

In particular, monitoring heart rate variability and the QT interval on an electrocardiogram can be used to evaluate a patient's autonomic function status. Heart rate variability denotes the extent of fluctuation in heart rate intervals, serving as a surrogate for sympathetic and parasympathetic nerve activity. The QT interval, measured from the beginning of the Q wave to the end of the T wave on an electrocardiogram, also serves as a proxy for changes in cardiac autonomic tone.

By monitoring these indicators, the status of a patient's autonomic function can be evaluated, and the risk of rebleeding can be predicted. For instance, prolongation of the QT interval or reduction of heart rate variability may indicate autonomic dysfunction and an increased risk of rebleeding. At this point, preventive measures, such as strengthening medication and improving lifestyle, can be implemented to mitigate the incidence of rebleeding.

4. The value of the electrocardiogram in the prediction of rebleeding in acute cerebral hemorrhage

Traditional ECG indicators have limited value in predicting acute cerebral hemorrhage rebleeding. For instance, an elevated heart rate and a prolonged QT interval are strongly linked to the risk of acute cerebral hemorrhage rebleeding. Furthermore, arrhythmia is a frequent complication of acute cerebral hemorrhage with rebleeding, and ECG plays a crucial role in diagnosing and monitoring arrhythmia.

New electrocardiographic indices, such as cardiac autonomic tone and electrocardiographic information entropy, hold significant value in forecasting rebleeding in acute cerebral hemorrhage. Cardiac autonomic tone denotes the magnitude of cardiac sympathetic and parasympathetic tone, whose fluctuations can offer insights into the heart's functional and metabolic status. On the other

hand, cardiac information entropy refers to the measurement of information content in ECG signals, which can reflect the complexity and stability of the heart's electrical activity. Previous studies have demonstrated that these novel ECG indicators, particularly cardiac autonomic tone and ECG information entropy, exhibit high accuracy in predicting rebleeding in acute cerebral hemorrhage, suggesting their potential as novel methods for forecasting this medical condition.

ECG-based cardiac information entropy, a method to assess the complexity and regularity of the heart's electrical activity through information processing and analysis of ECG signals, holds certain application value in the research and diagnosis of cardiovascular and cerebrovascular diseases. In studies on cerebral hemorrhage rebleeding, ECG-based entropy of cardiac electrical information can serve as a predictor and assessor of the condition.

Studies have demonstrated a correlation between cerebral hemorrhage rebleeding and abnormalities in the electrical activity of the heart. Additionally, ECG information entropy can indicate the patient's vital signs and changes in condition, enabling doctors to adjust treatment plans and make timely prognostic judgments.

Specifically, ECG-based ECG information entropy has the ability to predict and assess cerebral hemorrhage rebleeding. While treating cerebral hemorrhage patients, doctors collect and process ECG signals to calculate ECG information entropy. By comparing changes in entropy values before and after treatment, they can evaluate the patient's condition and assess the treatment's effectiveness. Additionally, ECG information entropy can be employed for prognostic assessments in patients with cerebral hemorrhage. Monitoring patients' vital signs and changes in ECG signals allows for predictions regarding the risk and likelihood of recurrent cerebral hemorrhage.

5. Conclusion

In conclusion, ECG-derived entropy analysis, a novel approach for processing and analyzing ECG information, holds significant potential in the field of cerebral hemorrhage rebleeding research. By monitoring and analyzing ECG information entropy, doctors can obtain more accurate and reliable diagnosis and treatment plans, thereby improving the therapeutic outcomes and prognosis of patients with cerebral hemorrhage.

Although studies on cerebral hemorrhage rebleeding utilizing cardiac autonomic tone and electrocardiographic information entropy have produced some results, these studies still suffer from several limitations. Firstly, the sample sizes of these studies are often small and subject to potential biases. Secondly, the methods of these studies are relatively homogeneous and lack of cross-sectional comparisons and longitudinal observations. Furthermore, the results of these studies remain controversial and require additional validation and refinement.

6. Prospect

Although ECG has been shown to be valuable in predicting rebleeding in acute cerebral hemorrhage, further exploration is still needed. For instance, is there a correlation between traditional ECG indicators and new ECG indicators? How can we effectively combine these indexes to improve prediction accuracy? Additionally, current research primarily focuses on single ECG indices, but the combined application of multiple indices may enhance prediction precision. Future studies should address these questions to provide new insights into the prevention and treatment of acute cerebral hemorrhage rebleeding.

ECG holds substantial value in predicting the likelihood of acute cerebral hemorrhage rebleeding. Although numerous studies have demonstrated the diagnostic accuracy of both traditional and novel ECG indices in predicting acute cerebral hemorrhage rebleeding, further studies are needed to enhance prediction accuracy. Future research should prioritize the comprehensive application of

multiple ECG indices, exploring the correlation between traditional and novel ECG indices, to offer fresh ideas and strategies for managing acute cerebral hemorrhage rebleeding.

References

- [1] Bradley A. Gross, Brian T. Jankowitz, Robert M. Friedlander, et al. *Cerebral Intraparenchymal Hemorrhage: A Review [J]. JAMA, 2019, 321(13):1295-1303.*
- [2] MacWalter R S, Ersoy Y, Wolfson D R, et al. *Cerebral Haemorrhage. Parenchymal intracranial haemorrhage [J]. Gerontology, 2001, 47(3):119-130.*
- [3] Lu Victor M, Graffeo Christopher S, Perry Avital, et al. *Rebleeding drives poor outcome in aneurysmal subarachnoid hemorrhage independent of delayed cerebral ischemia: a propensity-score matched cohort study [J]. Journal of neurosurgery, 2019, 133(2):1-9.*
- [4] González-Duarte A, Cantú C, Rué-Sandoval J L, et al. *Recurrent primary cerebral hemorrhage: frequency, mechanisms, and prognosis [J]. Stroke, 1998, 29(9):1802-1805.*
- [5] Rodriguez-Luna David, Coscojuela Pilar, Rodriguez-Villatoro Noelia, et al. *Multiphase CT Angiography Improves Prediction of Intracerebral Hemorrhage Expansion [J]. Radiology, 2017, 285(3):932-940.*
- [6] Chen T, Xu G, Tan D, et al. *Effects of platelet infusion, anticoagulant and other risk factors on the rehaemorrhagia after surgery of hypertensive cerebral hemorrhage [J]. European review for medical and pharmacological sciences, 2015, 19(5):795-799.*
- [7] van Bree Maurits D R, Roos Yvo B W E M, van der Bilt Ivo A C, et al. *Prevalence and characterization of ECG abnormalities after intracerebral hemorrhage [J]. Neurocritical care, 2010, 12(1):50-55.*
- [8] Bhargava Pranshu, Singh Rahul. *Electrocardiographic Changes after Spontaneous Intracerebral Hemorrhage [J]. Indian Journal of Neurosurgery, 2019, 08(01):16-19.*
- [9] Bjelakovic Bojko, Dimitrijevic Lidija, Lukic Stevo, et al. *Hypertensive encephalopathy as a late complication of autonomic dysreflexia in a 12-year-old boy with a previous spinal cord injury [J]. European journal of pediatrics, 2014, 173(12):1683-1684.*
- [10] Li Caixia, Li Li, Zhang Jinfeng, et al. *Tripartite intensive intervention for prevention of rebleeding in elderly patients with hypertensive cerebral hemorrhage [J]. World journal of clinical cases, 2021, 9(33):10106-10115.*
- [11] Fehr Martha A, Anderson David C. *Incidence of progression or rebleeding in hypertensive intracerebral hemorrhage [J]. Journal of Stroke and Cerebrovascular Diseases, 1991, 1(3):111-116.*
- [12] Raj Ajith Bernardin, Lian LiFei, Xu Feng, et al. *Association of Satellite Sign with Postoperative Rebleeding in Patients Undergoing Stereotactic Minimally Invasive Surgery for Hypertensive Intracerebral Haemorrhage [J]. Current medical science, 2021, 41(3):565-571.*
- [13] Zheng Wenjian, Li Liangming, Zhu Yonghua, et al. *Impact of Surgeon Experience on Postoperative Rehemorrhage in Spontaneous Basal Ganglia Intracerebral Hemorrhage [J]. World Neurosurgery, 2019, 131:e402-e407.*
- [14] Patricia R.E. Harris. *The Normal Electrocardiogram [J]. Critical Care Nursing Clinics of North America, 2016, 28(3):281-296.*
- [15] Park Juyoung, Lee Kuyeon, Kang Kyungtae, et al. *Pit-a-Pat: A Smart Electrocardiogram System for Detecting Arrhythmia [J]. Telemedicine journal and e-health: the official journal of the American Telemedicine Association, 2015, 21(10):814-821.*
- [16] Bolin Elijah, Lam Wilson. *A review of sensitivity, specificity, and likelihood ratios: evaluating the utility of the electrocardiogram as a screening tool in hypertrophic cardiomyopathy [J]. Congenital heart disease, 2013, 8(5):406-410.*
- [17] Xiong Wenjuan, Nurse Ewan S, Lambert Elisabeth, et al. *Seizure Forecasting Using Long-Term Electroencephalography and Electrocardiogram Data [J]. International journal of neural systems, 2021, 31(9):2150039-2150039.*
- [18] Pang Trudy D., Nearing Bruce D., Verrier Richard L., et al. *T-wave heterogeneity crescendo in the surface EKG is superior to heart rate acceleration for seizure prediction [J]. Epilepsy & Behavior, 2022, 130:108670-108670.*
- [19] Duncan Jose R, MacDonald Erin J, Dorsett Katherine M, et al. *Does left ventricular hypertrophy by electrocardiogram predict adverse outcomes in pregnancies with chronic hypertension? [J]. The journal of maternal-fetal & neonatal medicine : the official journal of the European Association of Perinatal Medicine, the Federation of Asia and Oceania Perinatal Societies, the International Society of Perinatal Obstetricians, 2020, 33(10):1638-1642.*
- [20] Akinwusi P O, Oboro V O, Adebayo R A, et al. *Cardiovascular and electrocardiographic changes in Nigerians with a normal pregnancy [J]. Cardiovascular journal of Africa, 2011, 22(2):71-75.*
- [21] Kohei Hasegawa, Megan L. Fix, Lauren Wendell, et al. *Ischemic-appearing electrocardiographic changes predict myocardial injury in patients with intracerebral hemorrhage [J]. American Journal of Emergency Medicine, 2012, 30(4):545-552.*

- [22] Hjalmarsson Clara, Bergfeldt Lennart, Bokemark Lena, et al. *Electrocardiographic abnormalities and elevated cTNT at admission for intracerebral hemorrhage: predictors for survival?*[J]. *Annals of noninvasive electrocardiology: the official journal of the International Society for Holter and Noninvasive Electrocardiology, Inc*, 2013, 18(5):441-449.
- [23] Eker Amber, Yigitoglu Pembe Hare, Ipekdal H Ilker, et al. *Acute Onset of Intracerebral Hemorrhage due to Autonomic Dysreflexia* [J]. *Journal of Korean Neurosurgical Society*, 2014, 55(5):277-279.
- [24] Fares Souha A., Bakkar Nour Mounira Z., El Yazbi Ahmed F., et al. *Predictive Capacity of Beat-to-Beat Blood Pressure Variability for Cardioautonomic and Vascular Dysfunction in Early Metabolic Challenge* [J]. *Frontiers in Pharmacology*, 2022, 13:902582-902582.
- [25] Qiu Miaoyan, Sato Shoichiro, Zheng Danni, et al. *Admission Heart Rate Predicts Poor Outcomes in Acute Intracerebral Hemorrhage: The Intensive Blood Pressure Reduction in Acute Cerebral Hemorrhage Trial Studies* [J]. *Stroke*, 2016, 47(6):1479-1485.
- [26] Miwa Kaori, Koga Masatoshi, FukudaDoi Mayumi, et al. *Effect of Heart Rate Variabilities on Outcome After Acute Intracerebral Hemorrhage: A Post Hoc Analysis of ATACH-2* [J]. *Journal of the American Heart Association*, 2021, 10(16):e020364-e020364.
- [27] Loggini Andrea, Mansour Ali, El Ammar Faten, et al. *Inversion of T Waves on Admission is Associated with Mortality in Spontaneous Intracerebral Hemorrhage* [J]. *Journal of Stroke and Cerebrovascular Diseases*, 2021, 30(6):105776-105776.
- [28] Satoru Takeuchi, Kimihiro Nagatani, Naoki Otani, et al. *Electrocardiograph abnormalities in intracerebral hemorrhage* [J]. *Journal of Clinical Neuroscience*, 2015, 22(12):1959-1962.
- [29] Frangiskakis J Michael, Hravnak Marilyn, Crago Elizabeth A, et al. *Ventricular arrhythmia risk after subarachnoid hemorrhage.* [J]. *Neurocritical care*, 2009, 10(3):287-294.
- [30] Sakr Yasser L, Lim Noelle, Amaral André K B, et al. *Relation of ECG changes to neurological outcome in patients with aneurysmal subarachnoid hemorrhage* [J]. *International journal of cardiology*, 2004, 96(3):369-373.
- [31] Hanne Christensen, Anders Fogh Christensen, Gudrun Boysen, et al. *Abnormalities on ECG and telemetry predict stroke outcome at 3 months* [J]. *Journal of the Neurological Sciences*, 2005, 234(1):99-103.
- [32] Kailash Kumar Rahar, Hans Raj Pahadiya, Kishan Gopal Barupal, et al. *The QT dispersion and QTc dispersion in patients presenting with acute neurological events and its impact on early prognosis* [J]. *Journal of Neurosciences in Rural Practice*, 2016, 7(1):61-66.