

Research Progress on the Causes of Failure and Revision of High Tibial Osteotomy

Wan Qingming^{1,2,a}, Han Jin^{1,2,b}, Xu Chen^{1,2,c}, Huang Xiaoqiang^{3,d,*}

¹*Xi'an Medical University, Xi'an, Shaanxi, 710068, China*

²*Department of Orthopedics, Honghui Hospital of Xi'an Jiaotong University, Xi'an, Shaanxi, 710054, China*

³*Department of Orthopedics, Xi'an Fifth Hospital, Xi'an, Shaanxi, 710082, China*
^a1392876742@qq.com, ^b610050884@qq.com, ^c18395185028@163.com, ^dhuangxq73@163.com
**Corresponding author*

Keywords: High tibial osteotomy; Revision; osteoarthritis; Total knee replacement

Abstract: In order to summarize the reasons for the failure of tibial high osteotomy and the research progress of revision surgery. We consulted the literature on HTO in recent years widely, and summarized the causes and solutions of surgical failure. Resultly, the reasons for HTO failure include improper selection of indications, insufficient surgical techniques and other factors. Applying computers and 3D printing can reduce its failures. There are two options for revision surgery after HTO failure, including UKA or TKA revision, with adequate preoperative evaluation prior to implementation. The biggest challenge in revision surgery is the management and reconstruction of bone defects. In conclusion, HTO is at risk of failure, which still needs to be treated with caution, and the renovation plan should be decided according to the reason for the failure.

1. Introduction

High tibial osteotomy is a globally recognized option for treating ventricular osteoarthritis in the medial knee joint, especially for young and active patients. This procedure was first performed in 1958 [1] to correct the varus deformity by lateral mechanical axis shift [2,3]. Compared with another surgical type of total knee replacement, patients who underwent HTO surgery were able to retain their natural knee joint, so that the physical load was almost unaffected. And the patient's postoperative joint movement is close to the normal physiological state. At present, with the proposal of knee protection and osteoarthritis step treatment concept, it is becoming more and more important as a minimally invasive therapy for the treatment of knee osteoarthritis. Studies have shown osteotomy survival rates of 82 percent at 5 years, 55 percent at 10 years, and 28 percent after 10 years [4]. According to domestic and foreign studies, compared with TKA, the long-term follow-up rate of HTO is 11%~30% [5]. The vast majority of failure causes include progression of arthritis, pain with nonunion and avascular necrosis, nonunion, fracture of the tibial plateau, and lateral cartilage degeneration. Revision surgery is usually TKA, but UKA revision has been reported as a good option. The specific procedure to perform should be explored according to the actual physical condition of the patient. The purpose of this article is to review the factors of HTO surgery failure and the key

points of related revision surgery, so as to provide a reference for the clinical treatment of knee osteoarthritis.

2. Reasons for HTO failure

2.1. Selection of indications and surgical technical factors

In 2009, Annonziato proposed the ideal indication for HTO: Young patients (< 60 years old), with isolated medial osteoarthritis, good range of motion and no ligament instability, body mass index is a controversial factor; Some studies reported higher failure rates in milder patients, while others did the opposite. The low success rates of UKA and TKR in more severe patients give HTO an advantage in this regard [6]. Another study showed that when the tibial varus angle (TBVA) is greater than 5° or the medial proximal tibia angle (MPTA) is less than 85°, Patients with better postoperative outcomes and severe subchondral injury have difficulty achieving satisfaction after HTO [7]. The indications for HTO are increasing due to a better understanding of the biomechanics of the knee joint and improvements in surgical techniques. HTO can be used to treat chronic ligament instability (alone or in combination with ligament reconstruction/revision) or in association with cartilage resurfacing and meniscal repair or transplantation, and several clinical trials have shown ACL reconstruction with HTO to be effective. Risk factors for subsequent revision of HTO have been reported to be advanced age (>60 years), female sex, and the presence of other underlying medical conditions such as diabetes mellitus, osteoporosis, and hyperlipidemia [8]. Cotter [9] et al. found risk factors for short-term complications of HTO that age ≥45 years old and have an increased probability of any adverse events in other diseases such as diabetes mellitus and chronic obstructive pulmonary disease. So far, for patients with knee osteoarthritis, how to select HTO surgery according to indications still needs further research.

Gebhard et al. [10] believe that undercorrection and overcorrection often occur after HTO. These errors may be due to traditional perioperative incorrect radiological measurements and unstable fixation methods. These factors are one of the important reasons for HTO postoperative revision. Studies such as Xu [11] have found that under- or over-correction of HTO may lead to complications and surgical failure, while correcting misalignment with the aid of computer navigation provides more accurate and reproducible radiological results. In addition, a novel resorbable spacer can provide sufficient stability to the tibial osteotomy space, and the use of this spacer as a bone-inducing and biodegradable device can avoid secondary fixative removal surgery [12]. It improves imaging and knee function in patients with knee osteoarthritis. Ma [13] and other studies found that 3D printing individualized orthopedic osteotomy can use DICOM data from preoperative CT scan to create a knee joint model, simulate the opening after surgical osteotomy, correct alignment, accurately locate points, predict correction results, reduce intraoperative fluoroscopy, and help reduce surgery time and complications.

2.2. Other Factors

Surgical failure has been shown to include contralateral cortical hinge fractures, intra-articular fractures, unexpected changes in the posterior tibial oblique, disjointed or delayed healing at the osteotomy site, changes in patellar height, and infection [14]. Although surgical correction can relieve the patient's pain, it cannot stop the progression of medial arthritis. As medial arthritis progresses, patients need to have their knees revised or replaced after several years. Stuart [15] et al. observed radiographic progression of medial chamber arthritis 9 years after closed wedge HTO surgery in four out of five patients. One literature confirms that osteoarthritis progresses in 83.8 percent of cases and fails due to persistent pain in 16.2 percent [20]. Studies such as Giardini [16] have shown that the

postoperative complication rate of HTO is about 30%, including lateral hinge fractures, wound nonunion, and lateral tibial plateau fractures. The common causes are now broken down below.

2.2.1. Hinge fracture

Hinge fractures have been shown to be one of the most common causes of HTO failure, occurring in 15 to 25 percent of surgical procedures [17]. Martin [18] et al. reported lateral hinge fractures in 20% to 25% of HTO patients treated with TomoFix. A study of medium-term survival in high tibial osteotomy by Bourguennec et al. [19] found that the overall postoperative complication rate was 17%, with 11% for hinge fractures and 1% for joint fractures. Hinge fractures are one of the important factors in poor prognosis. After hinge fractures, non-locking plate fixation has a lower survival rate. Side hinge fractures were the most common complication, accounting for 16.7% of all complications in the included studies. Miltenberg [20] et al. found that lateral hinge fractures may lead to worse outcomes, as they may lead to increased micromovement at the osteotomy site and even lead to general instability of the proximal tibia. This may predispose the patient to loss of correction, overcorrection, and osteotomy nonunion, which may alter the rehabilitation regimen or require additional lateral stabilization. Recent studies have found that the length of the hinge during osteotomy is an important factor associated with lateral cortical fractures. In high tibial wedge osteotomy, limiting hinge length to less than 10 mm using tools such as hinge rupture consisting of patient-specific guidelines will help prevent hinge fractures. Therefore, consideration of the patient's bone condition, hinge location design, and safety distance are necessary steps to prevent contralateral cortical hinge fractures.

2.2.2. Progression of osteoarthritis

The theory of mechanics states that in a healthy knee, the mechanical axis passes through the center of the knee, so that the weight distribution of the two chambers is equal. However, in the knee with varus keratoarthrosis, the mechanical axis shifts medially, resulting in increased load on the medial chamber, which contributes to the progression of arthropathy. The concept of HTO surgery is based on moving a mechanical axis in order to distribute weight-bearing stress by correcting the deviated knee angle. Therefore, preoperative planning to determine correction is important and has a significant impact on postoperative outcomes. In a study by Odenbring et al. [21], only knees overcorrected using the closed wedge technique showed cartilage regeneration, while undercorrected knees did not. This indicates that this reflects the force in the medial chamber, which still exceeds the normal force. This leads to the progression of arthritis on this side, which is one of the causes of postoperative revision. One postoperative follow-up study of HTO noted that 132 (44%) patients progressed to Kellgren–Lawrence grade 1 or above, with an 8.6% annual risk of KL progression. Patients with medial chamber osteoarthritis and poor alignment are at increased risk of progression [22]. Therefore, conventional HTO has problems such as undercorrection and overcorrection that cause surgical failure, and Xu [11] and other studies have found that it provides more accurate and reproducible radiological results in correcting misalignment assisted by computer navigation, thereby increasing the success rate and survival rate of surgery.

2.2.3. Bone nonunion or delayed healing

Bone disunion or delayed healing is also one of the important causes of revision. In a retrospective analysis, bone nonunions accounted for approximately 1.9 percent of postoperative complications after HTO [23], possibly because very hard locking plates prevented sufficient micromovement to stimulate new bone formation during osteotomy close to locking plates. Röderer [24] et al. found that among 23 patients treated with HTO and locking plates, 65% had incomplete osteotomy and healing.

The osteotomy space near the steel plate remained open, and all patients presented with cortical defects. Autologous iliac bone grafting as a bone space filler in heavy smokers, obese patients, and patients with an open space greater than 10 mm has been found to accelerate imaging healing of bone, but there appears to be no advantage in conventional patients [25]. Similar studies have found that smoking is an important risk factor for predicting delayed and bone nonunion [26]. Jung [27] et al. compared the radioactive bone healing results of 137 knee patients who received HTO treatment, and patients who underwent autologous bone grafting and β -tricalcium phosphate had improved knee scores at the 6th month after surgery. In addition, Liu [28] et al. discovered a new m-shaped medial opening HTO surgery, and proved through clinical trials that although the serrated bone ends with a large cross-section are not significantly separated or even partially connected, the m-shaped osteotomy method has greater contact with cortical sections than the traditional transverse osteotomy method at the same gap opening distance. This improvement undoubtedly has a strong positive effect on the rapid healing of the osteotomy end.

2.2.4. Infection

Postoperative infection is also one of the important reasons for HTO revision, among which oblique skin incision and hospitalization for one day are risk factors for the development of infection, including the infection rate of needle bundle infection is 2~71%. Superficial infections account for 1 to 9 percent and deep infections account for 0.5 to 4.7 percent [29]. The same study found that the oblique incision was the only statistically significant parameter after HTO with surgical site infection, as persistent lymphedema distal to the scar was observed after the oblique incision. Lymphedema is a well-known risk factor for skin infection, and they found that longitudinal incisions appear to be very safe, with no single infection found in 90 patients [30]. Studies such as W-Dahl [31] have shown that patients with only one day hospital stay have a higher risk of developing *Staphylococcus aureus* at the wound site compared with those with a longer hospital stay. Smoking significantly impairs the oxygen distribution of tissues and has a negative effect on wound healing and tissue regeneration. Studies have shown that smoking is associated with higher rates of infection and deep infection. Multivariate analysis also suggests that postoperative infection tends to be associated with smoking, although this association is not obvious. Obesity is considered a risk factor for infection after various orthopedic and traumatic surgical procedures. A single study can identify [32] obesity as a risk factor for developing bone nonunion after HTO. While it seems likely, the exact role of obesity in post-HTO infection development remains unclear and should be investigated in future studies. Studies suggest that the key to infection treatment is to remove the hardware as soon as it heals. Relapse was found in all hardware-sparing settings, and gentamicin was used for irrigation and debridement [18].

2.2.5. Neurovascular injury

Intraoperative neurovascular injury during HTO surgery is also a cause of surgical failure, with a low incidence of popliteal artery injury, which is rarely reported as popliteal artery injury, which requires vascular surgeons to repair with autologous vascular grafting. In addition, the incidence of peroneal nerve injury after lateral closed wedge HTO (3.2 percent) was higher than that of medial open wedge HTO (0.4 percent) [23]. In one case report, an excessively long metal needle and 4.5 mm cortical tensile screw in an intermedial open wedge HTO injured the tibial nerve through the first distal foramen of the subosteotomy fixation plate, resulting in postoperative calf tingling and hypoesthesia [33]. Shim et al. [34] retrospectively analyzed 275 patients who received HTO for knee arthritis, 87 patients using the lateral hinge-guided posteromedial fixation system (LCfit), compared with other systems, the distance from the neurovascular structure to the screw extension line was significantly farther, and the safety angle of the lateral posterior medial steel plate system was also

significantly wider, providing better postoperative CT analysis of neurovascular safety during steel plate fixation. Therefore, doctors should try to avoid neurovascular damage caused by surgical problems during surgery, and guide patients to recover after surgery.

3. Research progress in revision surgery

Clinical outcomes of high tibial osteotomy (HTO) deteriorate over time, and revision usually requires conversion to total knee arthroplasty (TKA), but medial single-chamber knee replacement (UKA) after HTO failure has also been reported as a good treatment. See Figure 1. Conversion to total knee replacement (TKA) after HTO failure is generally considered a technically demanding procedure. Many studies have highlighted issues including soft tissue problems, difficulty with patellar valgus, management of hardware-sparing hardware, management of coronal and sagittal deformities proximal to the tibia, and difficulty with ligament balance. Before HTO TKA, surgeons often need to consider limb malalignment, instability, joint stiffness, patellar pull, and surgical approach. A careful surgical plan should be prepared in advance and intraoperative problems should be anticipated. In view of these problems, we need to carry out perfect preoperative preparation, which is the guarantee to ensure the smooth progress of the operation and an effective way to improve the success rate of the operation. In recent years, digital orthopedic technologies such as computer navigation, robot-assisted artificial intelligence, 3D printing and other emerging technologies can help the surgical process be smoother and faster.

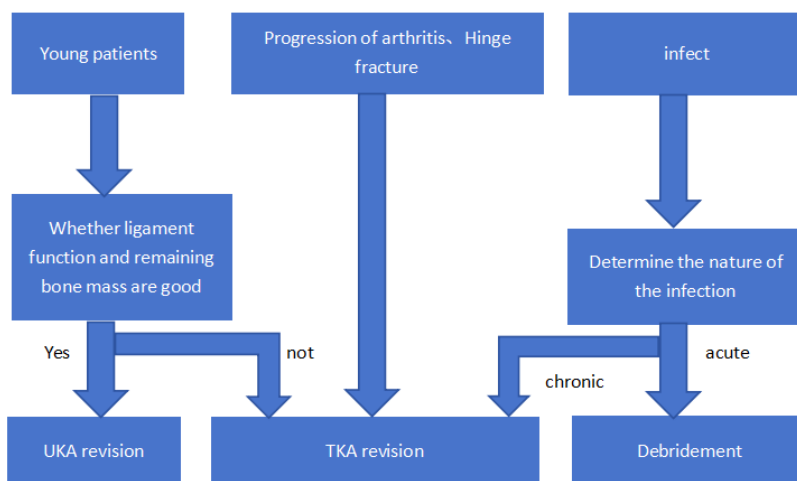


Figure 1: Reasons for renovation and corresponding plans

3.1. UKA revision

Although after HTO failure, the only revision option is total knee replacement (TKA). However, in younger patients with strong knee preservation desires, the lateral collateral ligament and remaining bone mass are good, and medial single-compartment knee replacement is also a good option. Jones [35] et al. showed us good treatment results in four cases of UKA after HTO failure, using patient-specific device (PSI) adjuvant technology to reverse previous osteotomy and perform medial UKA. The technique of 3D printed patient-specific guidelines is used to control the position of osteotomy, the degree of angle correction, and position the sawing of the single-chamber prosthesis according to the alignment of the corrected legs. Schlumberger [36] et al. retrospectively analyzed 27 cases of medial UKA refurbishment after HTO, and the survival rate was 93.0%. They showed that prior HTO was not a contraindication to medial UKA due to good outcomes in medium-term follow-

up in selected patients with medial osteoarthritis and previous HTO. Although the number of cases of UKA revision is relatively small, this method is an alternative to knee preservation.

3.2. TKA revision

Revision with TKA is the most commonly used treatment. In patients with revisioned TKA, obesity is the primary risk of TKA, as are advanced age and severity of cartilage damage that may lead to conversion to TKA. Studies such as Gupta [37] showed that 55 patients who had previously received HTO were treated with TKA. At a mean follow-up of 11.2 years, 89% had a good outcome and 11% had a poor outcome. Efe [38] et al. through TKA analysis after the first TKA and HTO showed that the range of motion of patients after previous HTO was significantly smaller, and the operation was more challenging, and it was associated with more postoperative complications. However, satisfactory results and good survival can be achieved at medium-term follow-up. In an analysis of the survival rate of total knee arthroplasty after high tibial osteotomy compared with primary total knee replacement, the primary TKA group had significantly higher survival rates at long-term follow-up than the TKA group with previous HTO [39]. A retrospective analysis showed that in 144,692 cases, there were significantly more corrections and complications in postoperative x-rays in the HTO-TKA group, such as tibial prosthesis loosening and postoperative impingement. The risk of revision is significantly higher compared with primary TKA [40].

In summary, compared with TKA modified HTO, the survival rate of prosthesis is not advantageous and may need to be re-modified to TKA, but the advantage of UKA renovations is that they are minimally invasive and well restored. Although TKA revision can achieve better stability and functional improvement, its postoperative survival rate is lower than that of primary TKA, and complications are more than that of primary TKA. Therefore, we should sum up experience, fundamentally recognize the existing problems, constantly reflect and improve it.

4. Summary and outlook

HTO is an important way to treat knee osteoarthritis, which is different from total knee replacement in that it is less damaging to patients and can preserve the natural knee joint. There are many reasons for its failure, most of which are controllable. Although the difficulty of revision is low, the knee function and clinical score of patients after revision are lower than that of the initial TKA, so the choice of patients with knee arthritis in HTO treatment needs to be more cautious. Excellent surgical technique and postoperative management are important guarantees to reduce their failure. Today's digital orthopedic technologies such as 3D printing and computer navigation and robot assistance can reduce the failure rate of HTO, and these emerging technologies have great advantages. The use of these techniques can improve survival and reduce revision rates, and can make the surgical process smoother.

References

- [1] Jackson JP, Waugh W. Tibial osteotomy for osteoarthritis of the knee [J]. *Acta orthopaedica Belgica*, 1982, 48(1):93-96.
- [2] Robert Gaasbeek, Roy Welsing, Marco Barink, et al. The influence of open and closed high tibial osteotomy on dynamic patellar tracking: a biomechanical study [J]. *Knee Surgery Sports Traumatology Arthroscopy Official Journal of the Esska*, 2007, 15(8):978-984.
- [3] Erik Hohmann, Adam Bryant, Andreas B Imhoff. The effect of closed wedge high tibial osteotomy on tibial slope: a radiographic study [J]. *Knee Surgery Sports Traumatology Arthroscopy*, 2006, 14(5):454-459.
- [4] Khoshbin Amir, Sheth Ujash, Ogilvie-Harris, Darrell, et al. The effect of patient, provider and surgical factors on survivorship of high tibial osteotomy to total knee arthroplasty: a population-based study [J]. *Knee Surgery Sports Traumatology Arthroscopy*, 2017, 25(3):887-894.

- [5] Legnani Claudio, Parente Andrea, Parente Franco, et al. Medial unicompartmental knee replacement is a viable treatment option after failed high tibial osteotomy: a systematic review [J]. *EFORT open reviews*, 2022, 7(8):569-575.
- [6] Amendola Annunziato, Bonasia Davide Edoardo. Results of high tibial osteotomy: review of the literature [J]. *International orthopaedics*, 2010, 34(2):155-160.
- [7] Peng Haining, Ou Aichun, Huang Xiaohong, et al. Osteotomy around the Knee: The Surgical Treatment of Osteoarthritis [J]. *Orthopaedic surgery*, 2021, 13(5):1465-1473.
- [8] Yoon Jung-Ro, Ko Seung-Nam, Jung Kwang-Young, et al. Risk of Revision Following Total Knee Arthroplasty or High Tibial Osteotomy: A Nationwide Propensity-Score-Matched Study [J]. *The Journal of bone and joint surgery. American volume*, 2019, 101(9):771-778.
- [9] Eric J Cotter, Anirudh K Gowd, Daniel D Bohl, et al. Medical Comorbidities and Functional Dependent Living Are Independent Risk Factors for Short-Term Complications Following Osteotomy Procedures about the Knee [J]. *CARTILAGE*, 2020, 11(4):423-430.
- [10] Gebhard Florian, Krettek Christian, Hifner Tobias, et al. Reliability of computer-assisted surgery as an intraoperative ruler in navigated high tibial osteotomy [J]. *Archives of orthopaedic and trauma surgery*, 2011, 131(3):297-302.
- [11] Xu Keteng, Wang Weichao, Wang Qin, et al. Comparison of computer-assisted navigated technology and conventional technology in high tibial osteotomy (HTO): a meta-analysis [J]. *Computer assisted surgery (Abingdon, England)*, 2022, 27(1):63-73.
- [12] Zhang Ruipeng, Li Shilun, Yin Yingchao, et al. Open-Wedge HTO with Absorbable β -TCP/PLGA Spacer Implantation and Proximal Fibular Osteotomy for Medial Compartmental Knee Osteoarthritis: New Technique Presentation [J]. *Journal of investigative surgery: the official journal of the Academy of Surgical Research*, 2019, 34(6):1-11.
- [13] Ma Xinlong, Hu Yongcheng, Wang Kunzheng, et al. Chinese Clinical Practice Guidelines in Treating Knee Osteoarthritis by Periarticular Knee Osteotomy [J]. *Orthopaedic surgery*, 2022, 14(5):789-806.
- [14] Song Sang Jun, Bae Dae Kyung, Kim Kang Il, et al. Conversion Total Knee Arthroplasty after Failed High Tibial Osteotomy [J]. *Knee surgery & related research*, 2016, 28(2):89-98.
- [15] Stuart M J, Grace J N, Ilstrup D M, et al. Late recurrence of varus deformity after proximal tibial osteotomy [J]. *Clinical orthopaedics and related research*, 1990, (260):61-65.
- [16] Giardini Piero, De Luca Lapo, Crespan Beatrice, et al. Does a lateral tibial plateau fracture (Takeuchi type III) occurring during opening wedge high tibial osteotomy induce a higher revision rate to total knee arthroplasty [J]. *Acta bio-medica: Atenei Parmensis*, 2022, 92(3):e2021558-e2021558.
- [17] Ryohei Takeuchi, Hiroyuki Ishikawa, Ken Kumagai, et al. Fractures Around the Lateral Cortical Hinge after a Medial Opening-Wedge High Tibial Osteotomy: A New Classification of Lateral Hinge Fracture [J]. *Arthroscopy: The Journal of Arthroscopic and Related Surgery*, 2011, 28(1):85-94.
- [18] Robin Martin, Trevor B. Birmingham, Kevin Willits, et al. Adverse Event Rates and Classifications in Medial Opening Wedge High Tibial Osteotomy [J]. *The American Journal of Sports Medicine*, 2014, 42(5):1118-1126.
- [19] Nicolas Bouguennec, Guillaume Mergenthaler, Thomas Gicquel, et al. Medium-term survival and clinical and radiological results in high tibial osteotomy: Factors for failure and comparison with unicompartmental arthroplasty [J]. *Orthopaedics & Traumatology: Surgery & Research*, 2020, 106(8S), S223-S230.
- [20] Miltenberg Benjamin, Puzitiello Richard N, Ruelos Verdinand C B, et al. Incidence of Complications and Revision Surgery After High Tibial Osteotomy: A Systematic Review [J]. *The American journal of sports medicine*, 2023, 3635465221142868-3635465221142868.
- [21] Odenbring S, Egund N, Lindstrand A, et al. Cartilage regeneration after proximal tibial osteotomy for medial gonarthrosis. An arthroscopic, roentgenographic, and histologic study [J]. *Clinical orthopaedics and related research*, 1992, (277):210-216.
- [22] Huizinga MR, Gorter J, Demmer A, et al. Progression of medial compartmental osteoarthritis 2-8 years after lateral closing-wedge high tibial osteotomy [J]. *Knee surgery, sports traumatology, arthroscopy: official journal of the ESSKA*, 2017, 25(12):3679-3686.
- [23] Miltenberg Benjamin, Puzitiello Richard N, Ruelos Verdinand C B, et al. Incidence of Complications and Revision Surgery After High Tibial Osteotomy: A Systematic Review [J]. *The American journal of sports medicine*, 2023, 3635465221142868-3635465221142868.
- [24] Gätz Räderer, Florian Gebhard, Lutz Duerselen, et al. Delayed bone healing following high tibial osteotomy related to increased implant stiffness in locked plating [J]. *Injury*, 2014, 45(10):1648-1652.
- [25] Fucentese Sandro F, Tscholl Philippe M, Sutter Reto, et al. Bone autografting in medial open wedge high tibial osteotomy results in improved osseous gap healing on computed tomography, but no functional advantage: a prospective, randomised, controlled trial [J]. *Knee surgery, sports traumatology, arthroscopy: official journal of the ESSKA*, 2019, 27(9):2951-2957.
- [26] van Houten Albert H, Heesterbeek Petra J C, van Heerwaarden Ronald J, et al. Medial open wedge high tibial

- osteotomy: can delayed or nonunion be predicted? [J]. *Clinical orthopaedics and related research*, 2014, 472(4):1217-1223.
- [27] Jung Woon-Hwa, Takeuchi Ryohei, Kim Dong-Hyun, et al. Faster union rate and better clinical outcomes using autologous bone graft after medial opening wedge high tibial osteotomy [J]. *Knee surgery, sports traumatology, arthroscopy: official journal of the ESSKA*, 2020, 28(5):1380-1387.
- [28] Liu Dejun, Liu Hongyuan, Li Yuanguo, et al. Application of a New M-shaped High Tibial Osteotomy Method: A Technical Note [J]. *Indian Journal of Orthopaedics*, 2023, 57(7):1153-1157.
- [29] Anagnostakos Konstantinos, Mosser Philipp, Kohn Dieter, et al. Infections after high tibial osteotomy [J]. *Knee surgery, sports traumatology, arthroscopy: official journal of the ESSKA*, 2013, 21(1):161-169.
- [30] Reischl Nikolaus, Wahl Peter, Jacobi Matthias, et al. Infections after high tibial open wedge osteotomy: a case control study [J]. *Archives of orthopaedic and trauma surgery*, 2009, 129(11):1483-1487.
- [31] W-Dahl Annette, Toksvig-Larsen Sören. Infection prophylaxis: a prospective study in 106 patients operated on by tibial osteotomy using the hemicallotaxis technique [J]. *Archives of orthopaedic and trauma surgery*, 2006, 126(7):441-447.
- [32] Meidinger Gebhart, Imhoff Andreas B, Paul Jochen, et al. May smokers and overweight patients be treated with a medial open-wedge HTO? Risk factors for non-union [J]. *Knee surgery, sports traumatology, arthroscopy: official journal of the ESSKA*, 2011, 19(3):333-339.
- [33] Shin Young-Soo, Sim Hyun-Bo, Yoon Jung-Ro, et al. Tibial nerve neuropathy following medial opening-wedge high tibial osteotomy-case report of a rare technical complication [J]. *European journal of orthopaedic surgery & traumatology: orthopedie traumatologie*, 2017, 27(4):563-567.
- [34] Shim Seung Jae, Jeong Ho Won, Park Sung Bae, et al. Reducing the Risk of Neurovascular Injury With Posteromedial Plating and Laterally Directed Screw Insertion During Opening-Wedge High Tibial Osteotomy [J]. *Orthopaedic journal of sports medicine*, 2022, 10(6):23259671221098421-23259671221098421.
- [35] Gareth G. Jones, Susannah Clarke, Martin Jaere, et al. Failed high tibial osteotomy: A joint preserving alternative to total knee arthroplasty [J]. *Orthopaedics & Traumatology: Surgery & Research*, 2018, 105(1):85-88.
- [36] Schlumberger Michael, Oremek Damian, Brielmaier Moritz, et al. Prior high tibial osteotomy is not a contraindication for medial unicompartmental knee arthroplasty [J]. *Knee surgery, sports traumatology, arthroscopy: official journal of the ESSKA*, 2020, 29:1-8.
- [37] Himanshu Gupta, Vivek Dahiya, Attique Vasdev, et al. Outcomes of total knee arthroplasty following high tibial osteotomy [J]. *Indian Journal of Orthopaedics*, 2013, 47(5):469-473.
- [38] Efe Turgay, Heyse Thomas J, Boese Christoph, et al. TKA following high tibial osteotomy versus primary TKA--a matched pair analysis [J]. *BMC musculoskeletal disorders*, 2010, 11(1):207.
- [39] Seo Seung-Suk, Nha Kyung-Wook, Kim Tae-Yeong, et al. Survival of total knee arthroplasty after high tibial osteotomy versus primary total knee arthroplasty: A meta-analysis [J]. *Medicine*, 2019, 98(30):e16609.
- [40] Chen Xi, Yang Zhen, Li Hairui, et al. Higher risk of revision in total knee arthroplasty after high tibial osteotomy: a systematic review and updated meta-analysis [J]. *BMC musculoskeletal disorders*, 2020, 21(1):153.